

The Long-term Survival of a Patient With Pancreatic Cancer With Metastases to the Liver After Treatment With the Intravenous α -Lipoic Acid/Low-Dose Naltrexone Protocol

Burton M. Berkson, Daniel M. Rubin, and Arthur J. Berkson

The authors describe the long-term survival of a patient with pancreatic cancer without any toxic adverse effects. The treatment regimen includes the intravenous α -lipoic acid and low-dose naltrexone (ALA-N) protocol and a healthy lifestyle program. The patient was told by a reputable university oncology center in October 2002 that there was little hope for his survival. Today, January 2006, however, he is back at work, free from symptoms, and without appreciable progression of his malignancy. The integrative protocol described in this article may have the possibility of extending the life of a patient who would be customarily considered to be terminal. The authors believe that life scientists will one day develop a cure for metastatic pancreatic cancer, perhaps via gene therapy or another biological platform. But until such protocols come to market, the ALA-N protocol should be studied and considered, given its lack of toxicity at levels reported. Several other patients are on this treatment protocol and appear to be doing well at this time.

Keywords: *pancreatic cancer; naltrexone; lipoic acid; survival*

J.A. is a 46-year-old man diagnosed with poorly differentiated adenocarcinoma of the pancreas with metastases to the liver. In early October 2002, J.A. started to feel vague abdominal pains as well as complained of symptoms associated with hyperacidity and indigestion. After his symptoms became more pronounced, he presented to the local emergency department where, secondary to his complaint of right lower quadrant abdominal pain, a computed tomography (CT) was performed on October 8, 2002. It revealed a hyperdense mass at the junction of the second and third portions of the duodenum and uncinate process of pancreas (Figure 1).

The mass had infiltrative margins, without local adenopathy. Furthermore, within the liver, there were at least 3 hyperdense lesions that were thought to possibly represent hemangiomas; a fourth lesion, 5 to 6

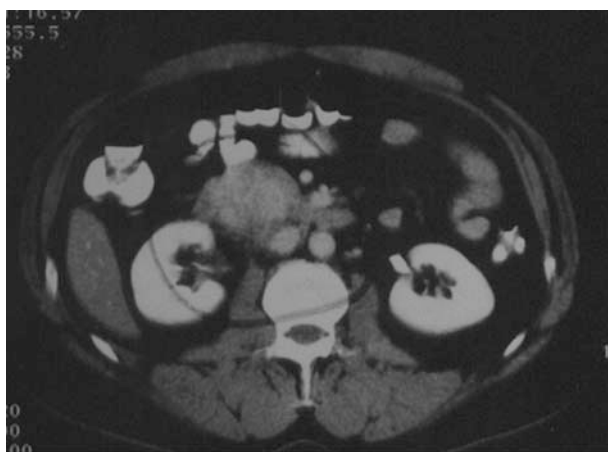

Figure 1 Computed tomography scan from October 8, 2002, shows a hyperdense mass at the junction of the second and third portions of the duodenum and the uncinate process of the pancreas (circled).

cm in diameter, contained some areas of hypodensity, thus suggestive of a neoplastic process (Figure 2).

Six days later, an esophagogastroduodenoscopy was performed, and an ulcerated Ampulla of Vater was biopsied; the pathology report was significant only for acute and chronic inflammation. One day later, magnetic resonance imaging (MRI) of the liver was performed in an attempt to classify the multiple hepatic lesions recognized on CT. The MRI suggested the lesions were not indicative of hemangiomas but rather of metastatic deposits. Subsequently, a 3.9 \times 3.9 cm mass was located associated with the head and

BMB is at the Integrative Medical Center of New Mexico and New Mexico State University, Las Cruces. DMR is in Scottsdale, Arizona. AJB is in the Department of Family Practice, University of Illinois at Chicago, Illinois Masonic Medical Center, and the Department of Family Practice, Advocate Health Center, Chicago, Illinois.

Correspondence: Daniel M. Rubin, 4300 North Miller Road, Suite 231, Scottsdale, AZ 85251. E-mail: rubin@rubinmedical.com.

DOI: 10.1177/1534735405285901

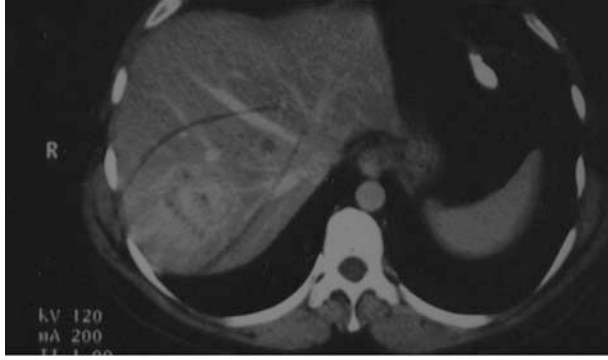


Figure 2 Computed tomography scan from October 8, 2002, shows multiple hyperdense masses within the hepatic parenchyma (circled).

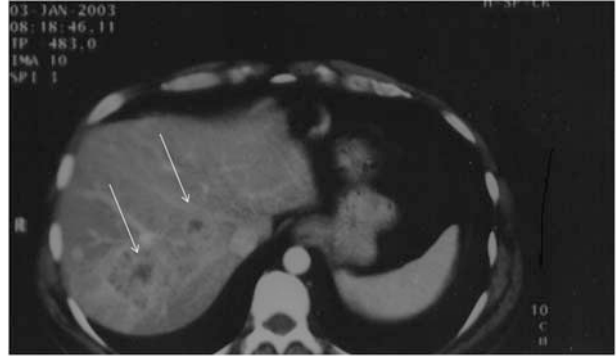


Figure 3 Computed tomography scan from January 3, 2003, shows stable hepatic parenchymal lesions as compared to October 8, 2002 (arrows).

uncinate process of the pancreas. This prompted a fine-needle aspiration of the largest liver lesion on October 22, 2002, and the diagnosis of poorly differentiated adenocarcinoma of pancreatic origin was made. Laboratory parameters reflecting J.A.'s functional hepatic status were at this time all within reference range; in addition, a common serum tumor marker for pancreatic cancer (CA 19-9) was within the reference range. Furthermore, this common marker has remained negative throughout the disease course.

Following this diagnosis, chemotherapy was prescribed. On November 7, 2002, J.A. began a 21-day course of gemcitabine (1000 mg/m²; actual dose = 1800 mg; day 1 and day 8) and carboplatin (AUC 5; actual dose = 600 mg; half dose on day 1 and half dose on day 8). The patient, after becoming leukopenic and thrombocytopenic and demonstrating poor subjective tolerance for the chemotherapy, decided to seek another opinion and traveled to a well-respected oncology center. After a complete oncology workup and review of his previous records, J.A., per his historical account, was told essentially that, given his situation, any further treatment would ultimately be fruitless.

Given this prognosis, on November 25, 2002, J.A. presented to the Integrative Medical Center of New Mexico (IMCNM) and was seen in consultation by one of the authors (B.M.B.). At the time of presentation, his review of systems was positive for seasonal allergies, heartburn, tinnitus, decrease in force of urinary stream, sleeping difficulty, weight loss, abdominal pain, and severe emotional stress and anxiety. Medications at arrival were Prevacid 30 mg, trimethoprim/sulfamethoxazole, Mylanta, Pepto-Bismol, and Roloids. B.M.B. added alprazolam 0.25 mg each bedtime as needed to help relieve J.A.'s nighttime anxiety.

An integrative medical program was then developed and prescribed for the patient. The purpose of this program was 3-fold: (1) nutritional support, (2)

comfort and palliation, and (3) immune stimulation. The key therapeutic agents were intravenous α -lipoic acid (ALA) 300 to 600 mg 2 days per week and low-dose naltrexone (LDN), 4.5 mg at bedtime. In addition, a triple antioxidant regimen consisting of oral ALA (600 mg/d), selenium (200 μ g 2 times per day), and silymarin (300 mg 4 times a day) was added to scavenge the products of oxidative stress that inevitably result from any serious chronic medical disorder. J.A. was also placed on a lifestyle program that included specific dietary advice.

After the first intravenous (IV) administration of the ALA, the patient improved subjectively, prompting his volunteered comment, "I have increased energy and a sense of well-being." The program was continued, and J.A. was extremely compliant.

On January 3, 2003, a repeat CT scan was performed using the same machine at the same diagnostic radiology department. Again, the mass at the head of the pancreas as well as the multiple hepatic lesions were demonstrated, and all lesions remained unchanged as compared to the scan of October 8, 2002 (Figure 3); furthermore, no new lesions were identified. The course of events was relatively uneventful as the patient continued on this integrative treatment plan.

On February 24, 2003, a repeat CT scan was performed (Figure 4; same CT machine, 51 days after the previous CT scan and 138 days after the initial CT scan), which again demonstrated unchanged pancreatic primary and metastatic hepatic lesions; no new lesions were identified.

As the patient continued on his treatment plan, follow-up CT scans were ordered at regular intervals. Both CT scans of April 21, 2003, and June 20, 2003 (Figure 5) revealed no changes in the existing lesions, nor any new lesions.

Another CT scan performed on August 19, 2003 (this time on a different machine at a different

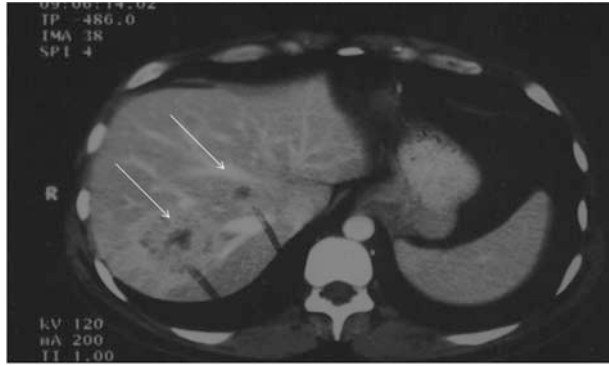

Figure 4 Computed tomography scan from February 24, 2003, shows stable hepatic parenchymal lesions as compared to January 3, 2003 (arrows).

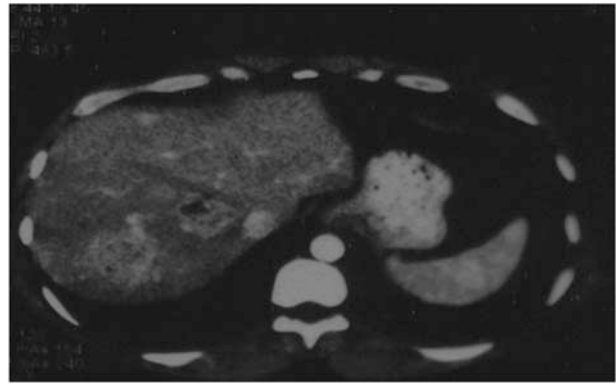


Figure 6 Computed tomography scan from December 2004 shows increase in size of the primary pancreatic lesion and increase in the number of the hepatic parenchymal lesions as compared to the June 20, 2003 scan (18-month interval).

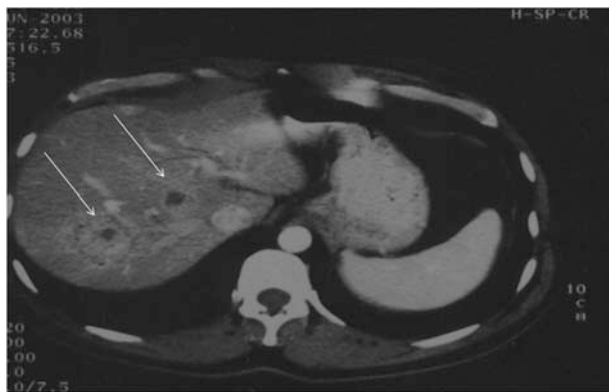


Figure 5 Computed tomography scan from June 20, 2003, shows stable hepatic parenchymal lesions as compared to February 24, 2003 (arrows).

institution) revealed stable primary and hepatic lesions with the potential development of 2 new lesions. However, a caveat by the interpreting radiologist read, "Two new visible lesions that were not clearly evident on the prior scan [June 20, 2003, different institution], but again this could be an artifact of a different phase of contrast enhancement rate/hr than a definite new finding. Otherwise stable CT of the upper abdomen." It is noted by the authors that no CT scan performed on J.A. has ever demonstrated evidence of biliary obstruction nor dilatation.

J.A. continued on his integrative protocol, without changes to his schedule, through March 2004, during which time CT images showed no changes in his disease status. The patient began to feel so well, with no symptoms of his disease, that he voluntarily discontinued his integrative treatment program. A positron emission tomography (PET)/CT fusion scan was performed on July 20, 2004, the results of which demonstrated disease advancement. Unfortunately, a subsequent CT scan performed in December 2004 demonstrated evidence of progressive disease at both

the primary and metastatic sites (Figure 6). The lesion at the head of the pancreas had increased in size to 5 cm transversely, and 8 hepatic lesions became recognizable, while the previously identified hepatic lesions showed a general increase in their sizes. In December 2004, because of the unsatisfactory scan results, J.A. resumed the IMCNM program. Since that time, J.A. has continued to improve subjectively, and he realized no disease progression in a June 2005 CT scan.

Discussion

The overall prognosis for patients with carcinoma of the pancreas is poor: the average length of survival after diagnosis ranges from 3 to 6 months.¹ Surgical resection is generally not an option for people with metastatic pancreatic cancer, and patients with advanced metastatic disease rarely survive more than a few months. The current dogma concerning this issue is that treatment should concentrate on the alleviation of pain and the improvement of quality of life with participation from palliative medical personnel.²

This leaves few options for such patients beyond chemotherapy and clinical trials. In this instance, J.A. chose to follow an integrative medical program that included intravenous ALA 300 to 600 mg twice a week, LDN 3 to 4.5 mg at bedtime, the oral triple antioxidant therapy protocol (developed by B.M.B.) consisting of (1) ALA 300 mg orally 2 times a day, (2) selenium 200 μ g orally 2 times a day, and (3) silymarin 300 mg 4 times a day, along with 3 professional-strength vitamin B complex capsules each day. It was also suggested that he follow the IMCNM lifestyle program including a strict dietary regimen along with a stress-reduction and exercise program.

That J.A. has had comparatively stable disease for more than a 3-year period is a remarkable clinical finding and prompts this report. It is the opinion of the

authors that the lack of progression of J.A.'s disease cannot be solely attributed to the single dose of chemotherapy he received. It has been reported that gemcitabine's effect on response rate and survival is disappointing.³ No data exist determining response to partial, moreover a single dose, of this drug either alone or in combination.

The stability of J.A.'s disease is thus attributable to the integrative program developed by one of the authors (B.M.B.). This is further evidenced by the quick progression of J.A.'s primary and hepatic lesions after his voluntary discontinuation of his integrative and successful treatment—an unfortunate but not uncommon decision. Many patients, despite strong encouragement from their physicians, will discontinue their treatments, in whole or in part, when faced with better health, diminishing financial resources, or both. The former is a subjective sensation often realized by patients when undergoing a treatment plan aimed at improving their overall health and as a result promoting an autogenous antitumor response. Non-medically trained patients tend to associate improved sense of well-being and reduction of paraneoplastic symptoms with the notion that they are improving and that continued treatment may not, indeed, be necessary. In addition, because nonconventional medical treatments are generally not covered by most insurance plans, long-term care of this type can become a financial burden, forcing a discontinuation of their treatments despite their desires or those of the treating physician. Thus, it becomes the duty of integrative physicians to bring to public attention, via publication, cases in which such treatment plans have demonstrated success.

When J.A. first presented to the clinic (IMCNM), his quality of life was poor. He was losing weight, exhausted both physically and emotionally, and experiencing almost constant abdominal pain and nausea. However, as mentioned above, after only 1 treatment of intravenous ALA, his symptoms began to resolve. Improvement in quality of life is a particular strength of nutritional programs, and its inclusion in a treatment plan for someone with advanced pancreatic cancer may be essential.

People with metastatic pancreatic cancer often suffer from weight loss. The mechanism behind this is generally well understood and involves a complex interplay of proinflammatory biological response modifiers⁴; however, such pathways will not be reiterated herewith. From a clinical point of view, and for J.A.'s case in particular, maintenance of body weight and provision of normal protein-calorie nutritional status is of paramount importance. As weight loss continues, an individual's appetite generally diminishes, thus accelerating the loss of lean body mass, which then

leaves the patient with even less endogenous resources to maintain health and fight disease. It is probable, from the course of this case, that had J.A. continued on his course of chemotherapy, he quite possibly would have developed frank cachexia followed by the deleterious consequences of such a syndrome, including death.

The first key component in J.A.'s treatment protocol was ALA. It is chiefly an antioxidant, which has also been shown to influence a variety of biological processes associated with oxidative stress including diabetes, liver disease, and cancer.⁵⁻⁸ ALA is a naturally occurring cofactor that is active in an assortment of enzymatic complexes that control metabolism. There have been a number of articles suggesting the utility of ALA in the treatment of various cancers. One article reported that ALA induced hyperacetylation of histones.⁹ In this study, human cancer cell lines became apoptotic after being exposed to ALA, while the same treatment of normal cell lines did not induce apoptosis.

Another indication of a mechanism whereby ALA might discourage the growth of cancer cells is its ability to stabilize NF- κ B transcription factor.¹⁰ Th1- and Th2-mediated immune system cells identify and react to pathogenic insults with various cell membrane receptors. Most of these receptors initiate a cascade of signal transduction events that eventually activate the master transcription factor NF- κ B. NF- κ B is able to bind to DNA after the phosphorylation and ubiquitin-mediated deactivation of its inhibitor I κ B and to affect the rate of transcription of certain deleterious genes that have NF- κ B binding sites. Because of this, NF- κ B plays a significant role in the regulation of inflammatory-induced gene function. High doses of ALA, when added to cell culture, have been shown to inhibit the activation of NF- κ B.^{11,12}

Additional data have demonstrated evidence of a mechanism by which ALA may contribute to the therapy for malignant disease: ALA can stimulate prooxidant-driven apoptosis in human colon cancer cells. This process is activated by an increased uptake of oxidizable substrates into the mitochondrion.⁸ In another study, ALA synergistically improved vitamin C cytotoxicity against cancer cells in tissue culture.¹³ Unlike ascorbate alone, ALA was equally effective against proliferating and nonproliferating cells.

One study evaluated an extensive population of people with advanced cancer for the biological considerations that are relevant to cancer cachexia.¹⁴ The parameters studied were serum levels of proinflammatory cytokines (IL-1 β , IL-6, TNF- α), IL-2, acute-phase proteins (C-reactive protein and fibrinogen), leptin, and others applicable to oxidative stress, such as reactive oxygen species, endogenous antioxidant

enzymes such as glutathione peroxidase, and superoxide dismutase. The authors observed that patients with advanced cancer exhibit a chronic inflammatory state with high-grade oxidative stress. The article also suggests that antioxidant agents such as ALA can stimulate the development and maturation of cancer-fighting lymphocytes. Therefore, in this way, ALA can promote the functional restoration of the immune system in individuals suffering the oxidative stress that results from advanced cancer.

In another study, ALA was shown to increase homocysteine concentrations within cancer cells in certain established cancer cell lines.¹⁵ The increased homocysteine concentrations were toxic to the malignant cells.

Another study demonstrated the effects of ALA on the proliferation of mitogen-stimulated human peripheral blood lymphocytes in comparison to its effects on the proliferation of 2 leukemic T-cell lines.¹⁶ The discriminating toxicity of ALA toward the cancer cell lines was shown by electron microscopy and was due to the induction of apoptosis. In addition, ALA noticeably increased the induction of IL-2 mRNA and IL-2 protein secretion in cancer cells. The authors suggested that the differential effects of ALA on normal and leukemic T lymphocytes may specify a new pathway toward development of therapeutic agents for cancer.

Another relevant article demonstrated the ability of ALA to correct the most significant functional defects of peripheral blood mononuclear cells (PBMC) isolated from advanced-stage cancer patients.¹⁷ Twenty patients (mean age = 64.6 years) with advanced cancers of the lung, ovary, endometrium, and head and neck were examined. The serum levels of IL-1 β , IL-2, IL-6, TNF- α , and sIL-2R were significantly higher in those with cancer than in patients with no known cancers. The addition of ALA (0.001 mM) into the PBMC cultures significantly increased the response of PBMC isolated from cancer patients and healthy subjects. After 24 and 72 hours of culture, the expression of CD25 and CD95 on PBMC isolated from cancer patients was significantly lower than that of PBMC isolated from healthy subjects. The addition of ALA into these cultures significantly increased the percentage of cells expressing CD25 as well as those expressing CD95. ALA thus had a positive effect on several important T-cell functions in people with advanced-stage cancer.

LDN was the second key ingredient in this case. Nocturnally dosed LDN blocks endogenous opiate receptors, a short-lasting effect. During this receptor blockade, the body produces large amounts of opiates in response to the positive feedback, which become available to and saturate said receptors, once the LDN

has been cleared from them. Opiates are powerful inducers of the Th1 immune response: in this sense, then, LDN produces an indirect immune response. LDN has a stimulatory effect on immune cells via an indirect interaction with their opiate receptors, whereas high-dose naltrexone has an inhibitory effect. The widely recognized pharmacologic effect of naltrexone is the competitive inhibition of membrane-based opiate receptors that consequently produce an opiate blockade. As a result of this action, patients who are addicted to opiates or are chronic ethyl alcohol users will not feel the normal "high" and should be inclined to discontinue these recreational activities. For this reason, naltrexone is considered an opiate antagonist.

Zagon and McLaughlin¹⁸ reported that very low-dose naltrexone slowed the growth of neuroblastoma cells in culture and suggested that it therefore may have a role in the treatment of certain cancers. In a 2003 article, the same authors suggested that the modulation of cancer cell growth in tissue culture was not the result of alterations in apoptosis or necrosis but from some other pathway.¹⁹

Malignant astrocytomas are believed to be incurable; therapy for such is aimed at palliation and overall survival. Lissoni et al²⁰ reported on the treatment of malignant astrocytomas with the administration of naltrexone plus radiotherapy (RT). The tumor regression rate in patients treated with RT plus naltrexone was slightly higher than that of those treated with RT alone, but the percentage of those surviving at 1 year was significantly higher in patients treated with RT plus naltrexone than in those treated with RT alone (5/10 vs 1/11, $P < .05$).

In a later article, Lissoni et al²¹ reported escalation of IL-2-dependent anticancer immunity by the administration of melatonin (MLT) plus naltrexone. The researchers found that these 2 agents were able to stimulate the Th1 and suppress the Th2 lymphocyte response. The results of their study also suggested that NTX amplified the lymphocytosis obtained by IL-2 plus MLT. In addition, the authors wrote that in view of the fact that lymphocytosis represents the most important favorable prognostic variable predicting the anticancer efficacy of IL-2 immunotherapy, the addition of MLT and naltrexone to IL-2-containing regimens warrants further testing.

Bihari²² first used LDN to treat people with AIDS: given his promising results, he later used LDN for the treatment of people with cancer. Over the years, he administered LDN to 450 patients with cancer, most of whom had failed the standard treatments.^{23,24} According to Bihari, of 354 patients who had regular follow-ups, 86 showed signs of noteworthy tumor shrinkage (at least a 75% reduction in tumor bulk), and at least

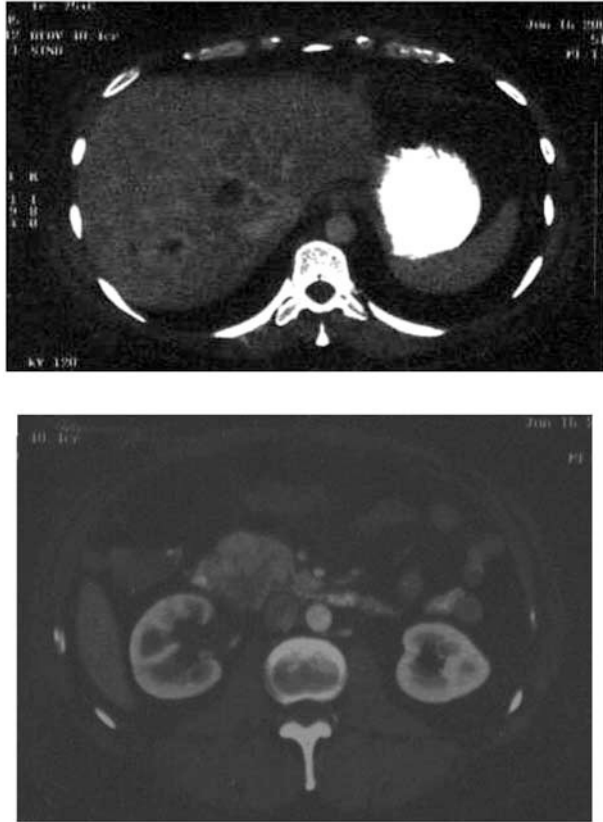


Figure 7 Computed tomography scan from June 2005 shows stable primary metastatic hepatic lesions (top) and stable shrunken primary pancreatic lesions (bottom) as compared to October 2002.

125 others were reported to have stabilized and appeared to be moving toward remission.

Conclusion

In this case report, we describe the treatment of a 46-year-old man who was diagnosed with metastatic pancreatic cancer in October 2002. He was initially surveyed and staged by a local oncology team and treated with a standard chemotherapy regimen. After a single treatment of gemcitabine and carboplatin, the patient became leukopenic and thrombocytopenic and could not tolerate any further chemotherapy. In addition, even with the standard chemotherapy protocol, his cancer progressed.

J.A. then arrived at the office of one of the authors (B.M.B.) and was promptly started on a program of intravenous ALA, LDN, and a healthy lifestyle program. During the period from October 2002 to present (December 2005), J.A.'s pancreatic cancer with metastases to the liver was followed closely by regular office visits and CT and PET scans, and he has remained mostly stable (Figure 7). It is interesting to note that J.A.'s disease progressed rapidly when he

went off the ALA-LDN therapy; however, it stabilized quickly when he resumed the treatment.

J.A. went back to work soon after he started the ALA-LDN integrative treatment protocol and remains free of symptoms at 3 years and 3 months. The authors believe that since most people with metastatic pancreatic cancer succumb to their disease miserably within a very short time, the 39-month survival time with non-progressive disease reported here represents a benchmark in oncology. People with metastatic pancreatic cancer more often die from their disease or complications thereof within 6 months and usually after a very stressful and painful course. The report above is thus of great importance.

In summary, the integrative therapy described in this article may have the possibility of extending the life of a patient who is customarily considered terminal. This was accomplished with a program of universal antioxidants, one that bears known antitumor activity (ALA) and an opiate-blockading agent that can stimulate an endogenous immune response. The authors believe that biomedical science will one day develop a cure for metastatic pancreatic cancer, perhaps via gene therapy or another biological-type platform. But until such protocols come to market, and moreover evolve and become realized, the ALA/LDN therapy should be considered given its lack of toxicity at levels reported herein, ready availability, and its effect on J.A., the true subject of this report.

B. Berkson declares no financial interest in the substances discussed in this paper but uses lipoic acid and naltrexone in his medical practice.

References

1. van Stieghmann G, Bornman P, Terblanche J. Carcinoma of the pancreas at Groote Schuur Hospital, 1975-1979. *S Afr Med J*. 1981;60:97-99.
2. Bornman P, Beckingham IJ. ABC of diseases of liver, pancreas, and biliary system: pancreatic tumours. *BMJ*. 2001;322:721-723.
3. Choi SB, Lee Hy, Yuh YJ, Kim SR. A phase 2 study of combination chemotherapy with gemcitabine, 5-fluorouracil, and cisplatin for advanced pancreatic cancer [in Korean]. *Korean J Gastroenterol*. 2005;45:348-353.
4. Brown TT, Zelnik DL, Dobs AS. Fish oil supplementation in the treatment of cachexia in pancreatic cancer patients. *Int J Gastrointest Cancer*. 2003;34:143-150.
5. Ziegler D. Thioctic acid for patients with symptomatic diabetic polyneuropathy: a critical review. *Treat Endocrinol*. 2004;3:173-189.
6. Berkson BM. A conservative triple antioxidant approach to the treatment of hepatitis C. Combination of alpha lipoic acid (thioctic acid), silymarin, and selenium: three case histories. *Med Klin (Munich)*. 1999;94(suppl 3):84-89.
7. Berkson BM. Thioctic acid in treatment of hepatotoxic mushroom (*Phalloides*) poisoning. *N Engl J Med*. 1979;300:371.
8. Wenzel U, Nickel A, Daniel H. Alpha-lipoic acid induces apoptosis in human colon cancer cells by increasing

- mitochondrial respiration with a concomitant O₂-generation. *Apoptosis*. 2005;10:359-368.
9. Van de Mark K, Chen JS, Steliou K, et al. Alpha-lipoic acid induces p27Kip-dependent cell cycle arrest in non-transformed cell lines and apoptosis in tumor cell lines. *J Cell Physiol*. 2003;194:325-340.
 10. Lee KY, D'Acquisto F, Hayden MS, et al. PDK1 nucleates T cell receptor-induced signaling complex for NF-kappaB activation. *Science*. 2005;308:114-118.
 11. Sokoloski JA, Hodnick WF, Mayne ST, et al. Induction of the differentiation of HL-60 promyelocytic leukemia cells by vitamin E and other antioxidants in combination with low levels of vitamin D3: possible relationship to NF-kappaB. *Leukemia*. 1997;11:1546-1553.
 12. Suzuki YJ, Aggarwal BB, Packer L. Alpha-lipoic acid is a potent inhibitor of NF-kappa B activation in human T cells. *Biochem Biophys Res Commun*. 1992;189:1709-1715.
 13. Casciari JJ, Riordan NH, Schmidt TL, Meng XL, Jackson JA, Riordan HD. Cytotoxicity of ascorbate, lipoic acid, and other antioxidants in hollow fibre in vitro tumours. *Br J Cancer*. 2001;84:1544-1550.
 14. Mantovani G, Maccio A, Madeddu C, et al. Antioxidant agents are effective in inducing lymphocyte progression through cell cycle in advanced cancer patients: assessment of the most important laboratory indexes of cachexia and oxidative stress. *J Mol Med*. 2003;81:664-673.
 15. Hultberg B. Modulation of extracellular homocysteine concentration in human cell lines. *Clin Chim Acta*. 2003;330(1-2):151-159.
 16. Pack RA, Hardy K, Madigan MC, Hunt NH. Differential effects of the antioxidant alpha-lipoic acid on the proliferation of mitogen-stimulated peripheral blood lymphocytes and leukaemic T cells. *Mol Immunol*. 2002;38:733-745.
 17. Mantovani G, Maccio A. Restoration of functional defects in peripheral blood mononuclear cells isolated from cancer patients by thiol antioxidants alpha-lipoic acid and N-acetyl cysteine. *Int J Cancer*. 2000;86:842-847.
 18. Zagon IS, McLaughlin PJ. Naltrexone modulates tumor response in mice with neuroblastoma. *Science*. 1983;221:671-673.
 19. Zagon IS, McLaughlin PJ. Opioids and the apoptotic pathway in human cancer cells. *Neuropeptides*. 2003;37:79-88.
 20. Lissoni P, Meregalli S, Fossati V, et al. Radioendocrine therapy of brain tumors with the long acting opioid antagonist naltrexone in association with radiotherapy. *Tumori*. 1993;79:198-201.
 21. Lissoni P, Malugani F, Malysheva O, et al. Neuroimmunotherapy of untreatable metastatic solid tumors with subcutaneous low-dose interleukin-2, melatonin and naltrexone: modulation of interleukin-2-induced antitumor immunity by blocking the opioid system. *Neuro Endocrinol Lett*. 2002;23:341-344.
 22. Bihari B. Efficacy of low dose naltrexone as an immune stabilizing agent for the treatment of HIV/AIDS [letter]. *AIDS Patient Care*. 1995;9(1):3.
 23. Bilhari B. LDN and cancer [Low Dose Naltrexone Web Site]. Available at: <http://www.lowdosenaltrexone.org>. Accessed December 8, 2005.
 24. Bilhari B. Keynote address. Presented at: First Annual Low Dose Naltrexone Conference at the New York Academy of Sciences; June 11, 2005; New York, NY.