


Revisiting the ALA/N (α -Lipoic Acid/Low-Dose Naltrexone) Protocol for People With Metastatic and Nonmetastatic Pancreatic Cancer: A Report of 3 New Cases

Integrative Cancer Therapies
8(4) 416-422
© The Author(s) 2009
Reprints and permission: <http://www.sagepub.com/journalsPermissions.nav>
DOI: 10.1177/1534735409352082
<http://icet.sagepub.com>


Burton M. Berkson, MD, MS, PhD,^{1,2} Daniel M. Rubin, ND, FABNO,³ and Arthur J. Berkson, MD¹

Abstract

The authors, in a previous article, described the long-term survival of a man with pancreatic cancer and metastases to the liver, treated with intravenous alpha-lipoic acid and oral low-dose naltrexone (ALA/N) without any adverse effects. He is alive and well 78 months after initial presentation. Three additional pancreatic cancer case studies are presented in this article. At the time of this writing, the first patient, GB, is alive and well 39 months after presenting with adenocarcinoma of the pancreas with metastases to the liver. The second patient, JK, who presented to the clinic with the same diagnosis was treated with the ALA/N protocol and after 5 months of therapy, PET scan demonstrated no evidence of disease. The third patient, RC, in addition to his pancreatic cancer with liver and retroperitoneal metastases, has a history of B-cell lymphoma and prostate adenocarcinoma. After 4 months of the ALA/N protocol his PET scan demonstrated no signs of cancer. In this article, the authors discuss the poly activity of ALA: as an agent that reduces oxidative stress, its ability to stabilize NF κ B, its ability to stimulate pro-oxidant apoptotic activity, and its discriminative ability to discourage the proliferation of malignant cells. In addition, the ability of low-dose naltrexone to modulate an endogenous immune response is discussed. This is the second article published on the ALA/N protocol and the authors believe the protocol warrants clinical trial.

Keywords

pancreatic cancer, naltrexone, low-dose naltrexone, LDN, ALA/N, α -lipoic acid, NF κ B, nuclear factor κ B, antioxidant, gemcitabine

In March of 2006, the authors published a case study describing the long-term survival of a man (JA) with a diagnosis of pancreatic adenocarcinoma with metastases to his liver.¹ The diagnosis was made following biopsy at a well-respected academic medical center. The gentleman was originally treated with a single dose of a standard chemotherapy protocol, which failed, and he was told to go home because his prognosis was hopeless.

Given this scenario, JA presented to the Integrative Medical Center of New Mexico (IMC²NM) and was seen in consultation by the author (BMB). An integrative medical program was then developed and prescribed for the patient. The purpose of the program was 3-fold: (1) nutritional support especially through specific antioxidant agents, (2) comfort and palliation, and (3) immune system modulation via biological response modification. The major therapeutic agents were intravenous (IV) α -lipoic acid (ALA), 300 to 600 mg, 2 days per week, and low-dose naltrexone (LDN), 4.5 mg by mouth at bedtime. In addition, a triple antioxidant regimen consisting of oral ALA (600 mg per day), selenium

(200 mcg twice daily), and silymarin (300 mg 4 times a day) was started. JA was also placed on a generally-accepted-as healthy diet and lifestyle program.

After the first IV administration of the ALA, the patient improved subjectively, prompting his voluntary comment, "I have increased energy and a sense of well-being." The program was continued, and JA was extremely compliant. After 3 months of α -lipoic acid and low-dose naltrexone (ALA/N) therapy, JA returned to work.

Presently, 78 months following initial diagnosis, JA appears and feels normal, and his CT scan displays attenuation of the pancreatic tumors and the hepatic metastases.

¹The Integrative Medical Center of New Mexico, Las Cruces, NM, USA

²New Mexico State University, Las Cruces, NM, USA

³Southwest College of Naturopathic Physicians, Scottsdale, AZ, USA

Corresponding Author:

Daniel M. Rubin, Southwest College of Naturopathic Physicians, 7331 E Osborn Dr, Suite 330, Scottsdale, AZ, 85251, USA
Email: rubin@naturopathicspecialists.com

In September of 2007, the same authors published a case study of a 61-year-old man with non-Hodgkins lymphoma.² He refused standard therapy for religious reasons. On presentation, he had baseball-sized lymph nodes in his cervical region and left groin as demonstrated by a PET scan; one node contained biopsy-proven malignancy. After 6 months of LDN therapy and only 2 weeks of IV ALA, a PET scan demonstrated radiological remission; at the time of this writing, he is still free of disease, 57 months after his diagnosis date.

The impact of our initial publication has caused several other patients with pancreatic cancer to present to the IMC/NM requesting access to the ALA/N protocol. Some of the more recent case studies are presented here.

Patient 1: GB

Mrs GB is a 71-year-old Californian woman who was diagnosed with gall-stone pancreatitis in 1996. She recovered from her symptoms and was placed on maintenance therapy. She had no further symptoms until presentation in February of 2006, when during physical exam, a mass was palpated in her epigastric region. A CT scan demonstrated both a large mass in the head of her pancreas as well as some hepatic parenchymal abnormalities, thought to represent metastatic deposits.

Soon thereafter, a fine-needle aspirate of the pancreas demonstrated mucinous adenocarcinoma. Despite her physicians' urging to quickly begin an intensive chemotherapeutic regimen, she declined because her religious beliefs precluded such a regimen. Subsequently, she was given a prognosis of 3 to 6 months of life if she did not undergo the proposed chemotherapy treatments.

Mrs GB's friend had read about the ALA/N protocol and suggested that she try the approach because she was left with no other reasonable treatment opportunities. GB came to the IMC/NM in September 2006 with complaints of only accelerating and profound chronic fatigue and abdominal pain. On physical exam GB was rather thin and pale, and a large mass was palpated in her upper abdomen. Her Carcinoembryonic Antigen (CEA) was 6.7 and her Carbohydrate Antigen 19-9 (CA 19-9) was 39.

A PET scan was then performed demonstrating a nodular focus of enhanced glucose metabolism in the right upper quadrant of the abdomen with numerous hypermetabolic areas in the liver (Figure 1). BMB did address the standard-of-care approach for her disease, which the patient again promptly declined. She was offered ALA/N, consented to such, and the treatment was initiated.

As the treatment regimen continued, Mrs. GB was followed carefully with periodic laboratory and physical exams. She continued to improve in all parameters: serologically, physically, and symptomatically. By February 2007 and again in March 2008, GB was declared to be in

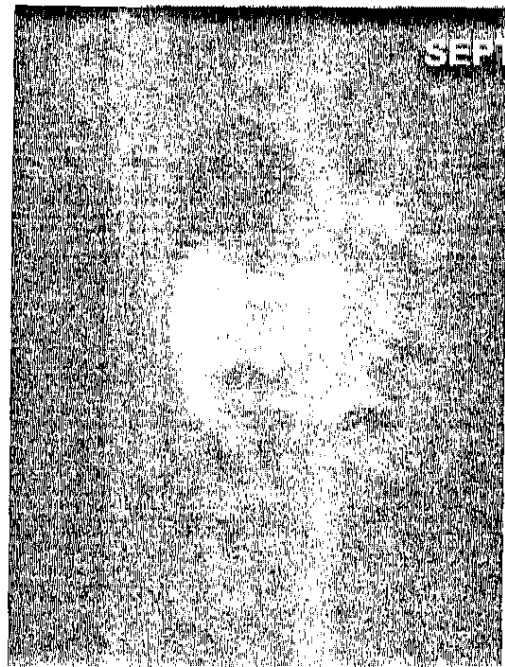

Figure 1. Mrs GB September, 2006

radiological remission by PET surveillance (Figures 2 and 3). Serologically, her CEA and CA 19-9 both normalized from 6.7 to 0.9 and from 39 to 18, respectively. At the time of this writing, 39 months after her diagnosis, GB continues with her treatment plan and has no signs of pancreatic disease.

Patient 2: JK

JK is an 80-year-old woman with generalized atherosclerotic vascular disease, diagnosed with adenocarcinoma of the pancreas with possible metastatic disease of the liver in September of 2005. Several months earlier, she began to feel very tired, developed nausea, and started to lose weight. Her general internist sent her to a gastroenterologist who ordered a CT scan and diagnosed a large lesion in the head of the pancreas with other lesions in the liver thought to be metastatic from the pancreas. A biopsy was performed on the pancreatic tumor in December 2005, and the pathology lab reported that it had missed the cancer. Mrs JK had a further workup at an academic hospital, and she was told that in spite of the negative biopsy, she had pancreatic cancer and was given a grim prognosis. No further treatment was suggested because of her advanced age. JK's family doctor, who was familiar with the innovative oncology literature, suggested that she try a nonstandard approach for her illness. She came to the IMC/NM in January of 2006.




Figure 2. Mrs. GB February, 2007




Figure 3. Mrs. GB March 2008

JK had to be helped by her friend into the exam room because she was too weak to walk and stand by herself. On physical exam, she was found to be cachectic and pale. Her skin was jaundiced and her sclerae were icteric. Her lungs

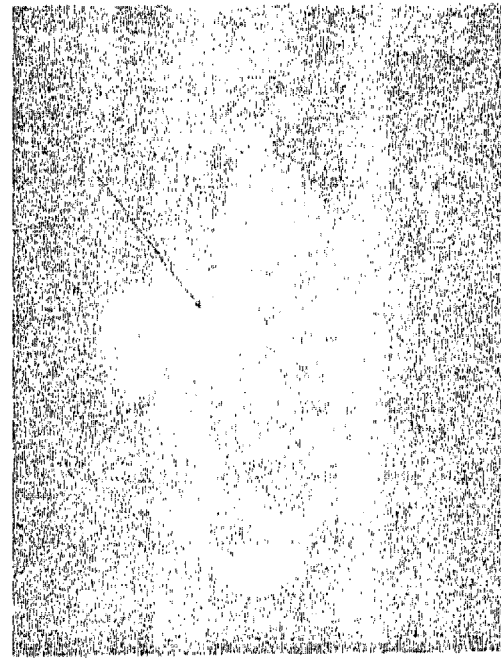


Figure 4. Mrs. JK January 2006

were clear and her heart had normal sounds and rhythm. A large mass was easily palpated in her epigastric region.

January 2006 laboratory results showed leucopenia, anemia, abnormal liver function, hyperglycemia, and a CA 19-9 of 353. A PET scan was performed and showed a large mass in the head of the pancreas with possible metastatic disease in the liver (Figure 4). The various standard treatment options were explained; however, JK stated her desire to delay such and in their place undergo the AIA/N protocol.

As the treatment regimen was initiated and continued, JK was followed carefully with periodic laboratory and physical exams. She continued to put on weight and have demonstrable serological improvement. In late June 2006 (5 months after her initial visit), a repeat PET scan was performed, this time demonstrating no signs of pancreatic adenocarcinoma (Figure 5). Mrs. JK continued her treatment program, and her health was maintained, symptom free.

In July of 2006, JK returned to her home in California and stopped her AIA/N treatment regimen. By August 2006, she began to feel ill once more; a CT scan was performed, which showed that the pancreatic adenocarcinoma had indeed returned. She expired in November 2006, 14 months following initial diagnosis.

Patient 3: RC

RC, a 67-year-old male was conventionally treated for prostate cancer with brachytherapy in 1996. In 1998, RC




Figure 5. Mrs JK June 2006

developed abdominal pain and was diagnosed with a diffuse large-cell lymphoma of B-cell origin. He was treated with 6 cycles of CHOP (cyclophosphamide, doxorubicin, vincristine, and prednisone) and radiation therapy.

RC developed painless jaundice in May of 2006 secondary to a distal, common bile duct obstruction. Exploratory surgery was performed revealing a nonresectable pancreatic carcinoma. He underwent a choledochoduodenostomy with gastrojejunostomy. The postoperative course became complicated by an abdominal infection requiring drainage and multiple courses of antibiotics. His external percutaneous biliary drain was never fully functional, resulting in recurrent episodes of cholangitis.

RC went to a large medical center in San Diego for a second opinion. A CT scan was performed, and it demonstrated pancreatic cancer, liver metastases, and peritoneal carcinomatosis. RC, too, was told that treatment would most likely yield little therapeutic benefit and that no treatment may be the favorable choice for him overall.

RC arrived at the IMC/NM in November 2006. He was emaciated and appeared in generally poor health. His CEA was 5.8 and his CA 19-9 was 53.6. A PET scan was performed, which showed hypermetabolic retroperitoneal lesions, both to the left and right, indicative of a large pancreatic tumor with numerous metastases to the liver (Figure 6). He was told that his disease process was well advanced and that an ALA/N protocol would be developed that could possibly prolong his life. Opting for this, RC was started on LDN 3.5 mg each night before bed along with IV ALA.

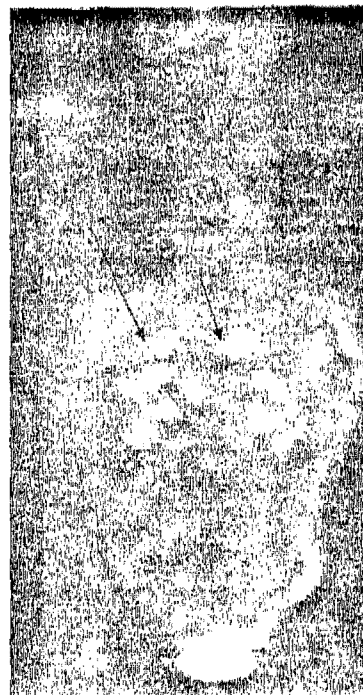


Figure 6. Mr RC November 2006

RC continued the ALA/N until February 2007 when another PET scan was performed. It showed a resolution of the previously demonstrated pancreatic and retroperitoneal lesions (Figure 7). RC was feeling so good that he was scheduled to have an internalization of the percutaneous biliary drain in March of 2007. He was examined by a medical oncologist who commented that at this point, RC had relatively little in the way of symptoms to palliate. The internalization of the biliary drain was performed, and on his medical oncologist's recommendation, he began a course of gemcitabine. Just before starting chemotherapy, his CEA had fallen from 53.6 to 2.6 and his CA 19-9 dropped from 146 to 113. His severe abdominal pain returned and because of the need for narcotics, RC was taken off his LDN. He soon developed septicemia, became unresponsive, and expired in May 2007, 12 months after initial diagnosis.

Discussion

In general, patients with advanced carcinoma of the pancreas have a very poor prognosis. The usual length of survival following initial diagnosis ranges from 3 to 6 months. In certain cases, surgical intervention is not an option, and patients with advanced disease rarely live more than a few weeks. The current view is that treatment should concentrate on palliative management.⁵

JA was a patient with biopsy-proven adenocarcinoma of the pancreas with metastases to the liver that we started




Figure 7. Mr. RC PET scan February 2007

treating with the ALA/N protocol in November 2002.¹ Just prior to this, and after 1 round of chemotherapy, JA was told by a reputable academic medical center that there was little hope for his survival. His progress is being followed by CT scans and PET scans, and he has done very well on the ALA/N protocol. Presently, 78 months after his initial presentation, he is back at work, free from symptoms, and without progression of his disease.

GB was diagnosed with pancreatic cancer in February of 2006. She refused the standard therapies because of religious reasons. She was started on the ALA/N protocol and is alive and free of signs and symptoms 39 months after initial diagnosis.

JK was diagnosed with pancreatic carcinoma with metastases to the liver in September of 2005. When she arrived at the clinic in January of 2006, her quality of life was poor. She was jaundiced and appeared cachectic. She was physically and emotionally exhausted, and complained of constant abdominal pain and nausea. After a few weeks of ALA/N therapy, her symptoms began to improve, and 9 months after diagnosis and 6 months following the initiation of therapy, her PET scan failed to demonstrate disease recurrence. During this period of 6 months, she felt essentially normal, without pain or nausea. After returning to her home state, her doctors refused to continue the ALA/N protocol. She subsequently had a brisk disease recurrence and succumbed to such in November 2006, 14 months following initial diagnosis.

RC carried the diagnoses of 3 primary malignancies: prostate adenocarcinoma, non-Hodgkin's lymphoma, and finally, pancreatic adenocarcinoma. He initially presented to

the IMC/NM with encephalitis, jaundice, and abdominal pain. He desired ALA/N protocol for his recent malignancy. He, therefore, quickly weaned himself off of his narcotic and subsequently began the L/DN component. Soon after starting the ALA/N protocol, RC began to feel better. He felt so good that he went to surgery to internalize his percutaneous biliary drain. Following surgery, he developed septicemia and died in May of 2007, 12 months following the diagnosis of pancreatic cancer.

The authors believe that the stability of the patient's disease is attributable to the ALA/N protocol developed by BMB. This is substantiated by our initial report in 2005, on patient JA.¹

These cases all represent, at the least, a restatement of a high quality of life for all patients who presented with pancreatic cancer. Such an achievement places the ALA/N protocol as a promising new treatment for people with this disease.

α -Lipoic Acid

ALA is the first component in the protocol. It is a naturally occurring cofactor that is active in an assortment of enzyme complexes that control metabolism, including the conversion of pyruvate to energy in the mitochondrion. ALA is also a vigorous free radical scavenger that has demonstrated the ability to reduce oxidative stress in a number of disorders, including diabetes, liver disease, and cancer.

There have been a number of articles suggesting the use of ALA in the treatment of various cancers. One article reported that ALA induced hyperacetylation of histones. Histones are proteins that are active in the proliferation of many types of cancer cells. Inhibition of such can drive a cell toward the apoptotic cascade. In this study, human cancer cell lines became apoptotic after being exposed to ALA, whereas the same treatment of normal cell lines did not induce apoptosis.¹

Another mechanism whereby ALA may discourage the growth of cancer cells is its ability to stabilize NF- κ B (nuclear factor κ B).² Under normal circumstances, NF- κ B dimers reside in the cytoplasm. However, if activated, the protein complex will translocate into the nucleus. On activation, it will launch the induction of more than 200 genes demonstrated to suppress apoptosis (create increased survival) and induce cellular transformation, proliferation, invasion, metastasis, chemoresistance, radio resistance, and inflammation.⁶ NF- κ B is a current and future target in oncology treatment. Modern pharmacological treatment has pointed toward NF- κ B, in that bortezomib, a novel proteasome inhibitor, inhibits NF- κ B as one of its valued demonstrations.

Additionally, Th1- and Th2-mediated immune system cells react to pathogenic insults with various cell membranous receptors. Many of these receptors start a cascade of

events that activate transcription factor NF κ B.⁵ Because of this, NF κ B plays a significant role in the regulation of inflammatory-induced gene function. High doses of ALA, when added to cell culture have been shown to inhibit the activation of NF κ B.⁷

Another article showed evidence of a mechanism by which ALA might be helpful in cancer therapy because of the fact that it can stimulate prooxidant-driven apoptosis in human colon cancer cells. This process is activated by an increased uptake of oxidizable substrates into the mitochondrion.⁸ In another study, ALA was shown to increase homocysteine concentrations within cancer cells in certain established cancer cell lines.⁹ The increased homocysteine concentrations were toxic for the malignant cells. An additional publication reported that ALA helped the proliferation of normal human lymphocytes and slowed down the proliferation of 2 leukemic T-cell lines.¹⁰ The discriminating toxicity of ALA was because of the induction of apoptosis in the leukemia cells. ALA also noticeably increased the induction of interleukin-2 (IL-2) mRNA and IL-2 protein secretion in cancer cells. The authors stated that the differential effects of ALA on normal and leukemic lymphocytes may specify a new pathway toward the development of therapeutic agents for cancer.

Mantovani and Maccio¹¹ demonstrated the ability of ALA to correct functional defects in peripheral blood mononuclear cells isolated from advanced stage cancer patients. Twenty patients with advanced cancers of the lung, ovary, endometrium, and head and neck were examined. The serum levels of IL-1 β , IL-2, IL-6, TNF- α , and sIL-2R were significantly higher in cancer patients than in patients with no known cancers. The addition of ALA into the cell cultures significantly increased the response of cancer patient mononuclear cells. This report demonstrated that ALA has a beneficial effect on immune cell function in advanced-stage cancer patients.

Naltrexone

LDN was the second key ingredient in the therapy of the patients. Nocturnally dosed LDN blocks endogenous opiate receptors for a very short time. During this receptor blockade, the body produces large amounts of opiates in response to the positive feedback. The endogenous opiates become available and saturate receptors on various cells in the immune system.

In 1995, Bihari¹² first used LDN to treat people with AIDS; given his promising results, he later used LDN for the treatment of people with cancer. Over the years, he administered LDN to 450 patients with cancer, most of whom had failed the standard treatments. According to Bihari, of 354 patients who had regular follow-ups, 86 showed at least a 75% reduction in tumor bulk, and 125

others were reported to have achieved remission or were close to remission.¹³

Zagon and McLaughlin¹⁴ reported that LDN slowed the growth of neuroblastoma cells in culture and suggested that it may have a role in the treatment of certain cancers.

Malignant astrocytomas are not believed to be curable, and treatment is aimed at palliation. Lissoni et al¹⁵ reported on the treatment of this malignancy with naltrexone plus radiotherapy (RT). The tumor regression rate in patients treated with RT plus naltrexone was somewhat higher than those treated with RT alone, and the percentage of those surviving at 1 year was significantly higher in patients treated with RT plus naltrexone than in those treated with RT alone.

Conclusion

We are not certain if there is a synergistic or additive relationship between ALA and LDN. As of the time of this writing, there does not seem to be any directly common biochemical pathway. It is reasonable to think that there indeed is at least one of these effects or that their coadministration initiates a novel cascade of biological effects. It is reasonable to believe as well that one component of the ALA/N protocol bears greater therapeutic efficacy than the other. It is reasonable that certain histological types of pancreatic cancer will respond to ALA/N. This is the second article published on this subject, and we believe that this does warrant deeper clinical investigation via a clinical trial, especially given the poor clinical course often experienced by those diagnosed with metastatic pancreatic cancer.

In summary, the integrative therapy described in this article may have the possibility of extending the life of a patient who is customarily considered terminal. This was accomplished with a program of an antioxidant that bears known antitumor activity (namely, ALA) and an opiate blockade agent that can stimulate an endogenous immune response.

As we stated in our earlier article, we believe that biomedical science will one day develop a cure for metastatic pancreatic cancer, perhaps via gene therapy or another biological-type platform. But until such protocols come to market, moreover evolve and are realized, the ALA/N therapy should be considered, given its lack of toxicity at levels reported herein, its ready availability, and its effect on the 4 patients discussed in this current article.

Declaration of Conflicting Interests

The authors declared no conflicts of interest with respect to the authorship and/or publication of this article.

Funding

The authors received no financial support for the research and/or authorship of this article.

References

- Berkson, BM, Rubin D, Berkson AJ. The long-term survival of a patient with pancreatic cancer with metastases to the liver after treatment with the intravenous alpha-lipoic acid/ low-dose naltrexone protocol. *Integr Cancer Ther.* 2006;5: 83-89.
- Berkson, BM, Rubin D, Berkson AJ. Reversal of signs and symptoms of a B-cell lymphoma in a patient using only low-dose naltrexone. *Integr Cancer Ther.* 2007;6:293-296.
- Bornman P, Beckingham JI. ABC's of diseases of liver, pancreas, and biliary system: pancreatic tumours. *BMJ.* 2001;322: 771-773.
- Vin de Mark K, Chen JS, Sichel K, et al. Alpha-lipoic acid induces p27Kip1-dependent cell cycle arrest in non-transformed cell lines and apoptosis in tumor cell lines. *J Cell Physiol.* 2003;196:325-340.
- Lee KY, D'Acquisto F, Hayden MS, Shm JJ, Ghosh S. PDK1 nucleates T cell receptor-induced signaling complex for NF-kappaB activation. *Science.* 2005;308:114-118.
- Aggarwal BB, Shishodia S. Molecular targets of dietary agents for prevention and therapy of cancer. *Biochem Pharmacol.* 2006;71:1397-1421.
- Suzuki YI, Aggarwal BB, Packer L. Alpha-lipoic acid is a potent inhibitor of NF-kappa B activation in human T cells. *Biochem Biophys Res Commun.* 1997;189:1709-1715.
- Wenzel U, Nickel A, Daniel H. Alpha-lipoic acid induces apoptosis in human colon cancer cells by increasing mitochondrial respiration with a concomitant O2-•-generation. *Apoptosis.* 2005;10:359-368.
- Hultberg B. Modulation of extracellular homocysteine concentration in human cell lines. *Clin Chim Acta.* 2003;330:151-159.
- Pack RA, Hardy K, Madigan MC, Hum NH. Differential effects of the antioxidant alpha-lipoic acid on the proliferation of mitogen-stimulated peripheral blood lymphocytes and leukemic T cells. *Mol Immunol.* 2002;38:733-748.
- Mantovani G, Maccio A. Restoration of functional defects in peripheral blood mononuclear cells isolated from cancer patients by three antioxidants: alpha-lipoic acid and N-acetyl cysteine. *Int J Cancer.* 2000;86:842-847.
- Bilani B. LDN and cancer. http://www.lowdosenaltrexone.org/ldn_and_cancer.htm. Accessed December 8, 2008.
- Bilani B. Keynote address. Presented at: first annual Low Dose Naltrexone Conference at the New York Academy of Sciences, June 11, 2005; New York, NY.
- Zagon IS, McLaughlin PJ. Naltrexone modulates tumor response in mice with neuroblastoma. *Science.* 1983;221:671-673.
- Lissoni P, Merzatti S, Fossati V, et al. Radioendocrine therapy of brain tumors with the long acting opioid antagonist naltrexone in association with radiotherapy. *Immun.* 1993;79:198-201.